



*Case Report*

## Management of Obstructive Sleep Apnea Syndrome in Obese Children

Vina Rosalina, Maria Mexitalia, Dwi Wastoro

Department of Pediatrics Faculty of Medicine Diponegoro University/Dr. Kariadi Hospital Semarang Indonesia

### Abstract

**Background** : Obstructive Sleep Apnea Syndrome (OSAS) is strongly associated with obesity. The common presenting complaints are excessive daytime sleepiness and loud snoring which potential for significant comorbidity of metabolic syndrome and decreasing in quality of life.

**Case** : An 11-year-old obese boy was referred to Dr. Kariadi Hospital with complaints of fatigue and frontal headache. His mother reported the loud snoring, apneic events during the night, excessive daytime sleepiness, increased irritability, and difficulty of school learning. Imaging studies showed cardiomegaly, adenoidal/nasopharyngeal ratio 0.714; opaque mass on cervical and airway space narrowing. Tympanometric audiogram showed mild right conductive hearing loss. The patient was diagnosed with OSAS, chronic and hypertrophic adenotonsillitis, severe hypertension, dilated right ventricle, right conductive hearing loss, obesity. The boy was undergone adenotonsillectomy and management of weight loss. Antihypertensive and other supportive medication were given and good results.

**Discussion** : The recommended initial treatment, even in obese children, consists of surgical removal of the adenoids and tonsils.<sup>5,6</sup> Several studies have shown that adenotonsillectomy reverses the symptoms and confirm the beneficial effects for OSAS on children's growth, school performance, improvements in PSG, behavior, QoL and cardiac function. The success rate for adenotonsillectomy in the context of OSA was approximately 85%.

**Conclusion** : Adenotonsillectomy and weight reduction is considered to be the primary intervention for OSAS children. Because the case had also severe hypertension, antihypertensive and other supportive medicine were give and had a good result.

**Keywords** : OSAS, obesity, children, adenotonsillectomy

### Tatalaksana Obstructive Sleep Apnea Syndrome (OSAS) pada Anak Obesitas

### Abstrak

**Latar belakang** : *Obstructive Sleep Apnea Syndrome* (OSAS) berhubungan erat dengan obesitas. Gambaran yang paling sering muncul adalah lama tidur yang berlebihan sepanjang hari dan mendengkur yang berpotensi meningkatkan morbiditas sindroma metabolic dan menurunkan kualitas hidup.

**Kasus** : Seorang anak obesitas berumur 11 tahun dirujuk ke RSUP Dr. Kariadi dengan keluhan utama mudah lelah dan sering pusing. Dari anamnesis didapatkan bahwa anak mendengkur dengan keras, tidur lama pada siang hari, iritabel dan kesulitan mengikuti pelajaran di sekolah. Pada pemeriksaan radiologi didapatkan kardiomegali, rasio adenoid/nasofaring 0,714; terdapat massa opaquedi servikal dan penyempitan saluran nafas. Audiogram *tympanometric* memperlihatkan kurang pendengaran ringan. Penderita didiagnosis sebagai OSAS, *adenotonsillitis hipertrofi kronik*, kurang pendengaran dan obesitas. Dilakukan operasi adenotonsilektomi dan tatalaksana untuk menurunkan berat badan. Pemberian obat antihipertensi dan terapi suportif lainnya memberikan hasil yang baik.

**Pembahasan** : Tatalaksana yang direkomendasikan untuk OSAS dengan obesitas masa anak adalah adenotonsilektomi, yang akan memberikan efek menguntungkan pada pertumbuhan, tampilan akademik, peningkatan kualitas hidup, perilaku dan fungsi jantung. Keberhasilan terapi adenotonsilektomi sekitar 85%.

**Simpulan**: Adenotonsilektomi dan pengurangan berat badan merupakan terapi utama pada anak obesitas dengan OSAS. Pemberian obat antihipertensi dan tetapi suportif lainnya memberikan hasil yang baik.

**Kata kunci** : OSAS, obesitas, anak, adenotonsilektomi

## INTRODUCTION

The increasing prevalence of obesity in children seems to be associated with an increased prevalence of Obstructive sleep apnea syndrome (OSAS) in children, but its pathophysiology has not been sufficiently studied and is not well understood.<sup>1</sup> Possible pathophysiological mechanisms contributing to this association include the following: adenotonsillar hypertrophy due to increased somatic growth, increased critical airway closing pressure, altered chest wall mechanics, and abnormalities of ventilatory control.<sup>2,3</sup> There is some evidence that obesity and OSA may contribute to the progression of metabolic syndrome with a potential for significant morbidity and decreases in quality of life.<sup>4</sup>

The management of OSAS in obese children has not been standardized and often requires a comprehensive and longitudinal evaluation from a team with expertise in sleep, otolaryngology, nutrition, pulmonary and cardiovascular disease, and behavioral science.<sup>5</sup> Adenotonsillectomy is considered to be the primary intervention and also recommended for weight reduction.<sup>5-7</sup>

In this case, we report a case of obese boy having chronic and hypertrophic adenotonsillitis complicated by the presence of OSAS and an increased risk of several type of morbidity (cardiomegaly, severe hypertension, and conductive hearing loss) and suggests an approach to the management of these patient.

## CASE PRESENTATION

On April 7<sup>th</sup> 2011, an 11-year-old obese boy from Pekalongan who was referred to Dr. Kariadi Hospital for suspected OSAS with complaints of fatigue and frontal headache. His mother reported the occurrence of loud snoring, apneic events during the night, he cannot sleep in supine position and would rather sleep with sitting or prone position, excessive daytime sleepiness, increased irritability, impaired concentration, decreased mood and interest in daily activities that make the boy unable to follow the lessons at school (he repeated 1 grade of class in his school) and he also had hearing loss on both ears. His parents didn't pay attention to the frequency/how often the child would get awoken. Because of this symptoms, the boy feel hungry all day, and eating to much. He would get angry when the parents asked him not to eat too

much. He started to gain too much weight. The boy never had participation on school sports and never had physical exercise in home. The boy preferred to watch television all day. He was not taking any medication at the time of presentation.

In the preceding 6 years, the boy had a medical history for recurrent upper respiratory tract infection with symptoms of productive cough, dysphagia, cold (thick mucus), and often had intermittent low grade fever. The boy was taken to a general physician and was diagnosed with enlarged tonsil, he was given medications with no significant improvement. In the next visit to outpatient care, they suggested to do an operation for his enlarged tonsil, but the parents decided to postpone the operation. Over time the complaints were getting more severe and the parents got worried, the child was taken to Pekalongan hospital and was referred to Dr. Kariadi Hospital. The boy was hospitalized in Kariadi Hospital for 15 days with significant improvement, during his stayed the boy complaints often got awoken at night because of difficulty breathing, shortness of breath (more than 7 times per day) and loud snoring.

The boy had no history of hospitalizations, surgeries, or another chronic illness. On family history the parent also has obesity but they had no difficulty sleeping nor breathing, but there are no obesity presence in siblings or grandparents, no history of allergic, asthma, hypertension, thyroid disease, premature atherosclerosis, dyslipidemia, diabetes type 2, and cancer.

From nutritional history, the boy had excess quantity but low quality of dietary intake. He often had rice 3-4 times a day one big portion each, with complete side dishes. The boy often had meals, snacks and soft drink, and got awoken at night to eat, because he went with his mother who was peddling on the market, he could easily bought food on the market.

Physical examination revealed an 11 years old boy morbidly obese (his weight was 83.3 kg, height was 142 cm, and body mass index was 41 kg/m<sup>2</sup>). Based on the height, the normal weight was 37.30 until 50.21 kg.

General appearance showed conscious, not active, spontaneous breathing, with stridor, but there were no cyanosis. His OSAS Score was 2.55. His initial vital signs temperature was 37°C, respiratory rate 30 beats/minute, heart rate 100 beats/minute, blood pressure 140/100 mmHg and sleeping SpO<sub>2</sub> 91% while awake SpO<sub>2</sub> 97%.

**TABLE 1**  
**Daily body weight monitoring**

Day	1	2	3-4	5-6	7-8	9	13	14-15
Weight	83.3	83.3	82.1	81.6	81.3	82.4	80.6	80.4

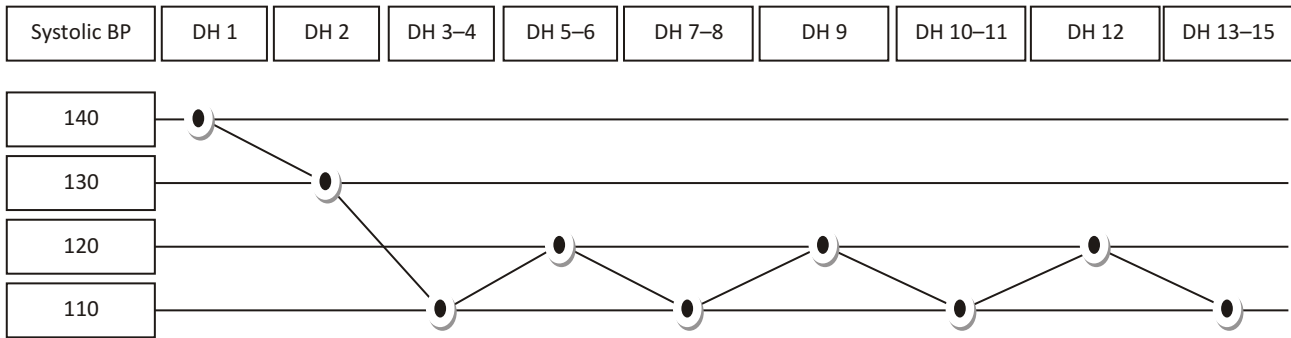


Figure 1. Daily systolic blood pressure monitoring

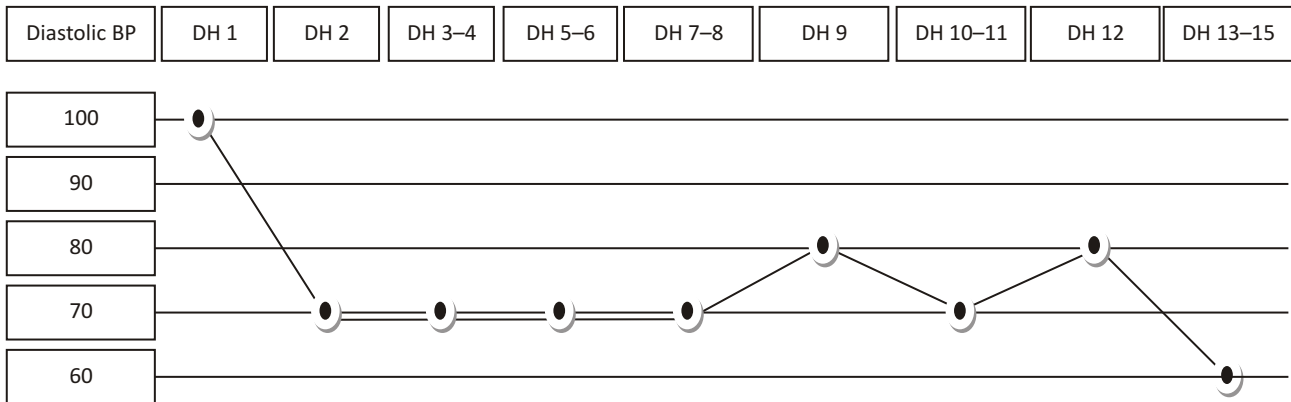


Figure 2. Daily diastolic blood pressure monitoring

His otolaryngologic evaluation showed no serumen, no discharge, no tragus tenderness, nose not flaring nostrils, no concha oedema, tonsil T4-4 with enlarged crypt not hyperemic, and granulations Ictus cordis is not visible palpable on left medioclavicular line of 5<sup>th</sup> intercostal space, no ictus cordis lift, heaving, thrill, heart configuration appearance is extending to laterocaudal, normal heart sound and lungs appear symmetrical, no retraction, clear breath sounds without no additional sounds. Normal abdominal examination. No found enlarged lymph nodes. Normal genital examination.

Laboratory examination showed Hb 15.8 gr/dl, Ht 47.3%, leukocyte 14,300/mm<sup>3</sup> (↑), platelet count 307,000/mm<sup>3</sup>, ureum 19 mg/dl and creatinine 0.83 mg/dl (with GFR 94.09 ml/minutes per 1.73 m<sup>2</sup>), blood glucose 115 mg/dl, cholesterol 165 mg/dl, triglyceride 145 mg/dl, HDL cholesterol 36 mg/dl, LDL cholesterol 134 mg/dl, sodium 139 mmol/L, potassium 3.9 mmol/L, chloride 104 mmol/L, calcium 2.37 mmol/L. Routine urine examination were within normal limit. From ophthalmology consultations reported emetropy eyes, with noo hipertensive retinopathy and arteriosclerosis on funduscopy, they suggested to schedule a follow up visit in 6 months.

Various imaging studies were performed including a chest X-ray which identify cardiomegaly (LA, LV) and no pulmonary abnormality, the adenoidal/nasopharyngeal ratio identify enlarged adenoid (= 0.714), cervical AP and Lateral Radiography identify opaque mass size ± 2.2x4 cm on cervical 1-2 level and airway space narrowing. Tympanometric audiogram showed mild right conductive hearing loss, left ear is within normal range. Electrocardiography regular sinus and no cardiomegaly. Nasopharyngoscopy showed deviated septum and narrow slit. Echocardiography showed dilated right ventricle. Endoscopy showed no hypertrophy of right and left inferior concha, narrow left and right inferior meatus, septum deviation, tonsil T4-4 (kissing tonsil).

The patient was diagnosed with obstructive sleep apnea (OSA), chronic and hypertrophic adenotonsillitis, severe hypertension, dilated right ventricle, right conductive hearing loss, obesity.

We managed this boy with comprehensive multidicipline care from the division of pulmonology, nutrition and metabolism, nephrology, cardiology and ENT departement. The boy were treated with oral antihypertensive captopril 3x12.5 mg, nifedipine 3x10 mg and furosemide 3x20 mg. The boy was given diet based

on step I diet the National Cholesterol Education Program (NCEP) recommendations for a eleven-year-old consisted of total calories 1930 kcal, total fat 579 kcal (64 g), saturated fat 193 kcal (21 g) contained of three times meals and three times 200 cc milk. Our program were monitor the patient's vital sign, blood pressure, hypertensive crisis, respiratory distress, the acceptability of the diet, body weight, pulse oximetry when sleeping and awake.

The boy undergone adenotonsillectomy on the 12th day of hospitalization in Kariadi hospital. After adenotonsillectomy the boy complaints snoring on supine position, sore throat (+) especially when swallowing, productive and painful cough (+) but improving in another clinical symptoms, without active bleeding on operation wounds with laboratory examination showed leucocytosis and another within normal limit. We give antibiotic injection ceftriaxone 1x2 gr and metronidazole 3x500 mg, analgetic injection ketorolac 3x30 mg, Metilprednisolone injection 3x1 vial, ranitidin injection 3x50 mg and others same with the previous day. On the fifteenth day of hospitalization the boy can be discharged and had been schedule to follow up visit. Antibiotic switching to oral cefixime 2x200 mg, and metronidazole 3x500 mg, tramadol 2x50 mg, ranitidine 3x1 tablet, dexamethasone 3x1 tablet and captopril 2x12.5 mg.

One weeks following his discharge from the hospital, the boy was follow up as an outpatient in our pulmonology division. He denied having headaches nor difficulty of breathing. His physical examination were normal. Result cervical soft tissue x ray showed no homogen opacity with clearly demarcated margin on C1-2 level, no airway narrowing, straight alignment, no lysis, no lytic nor destructive lesion on bone, corpus, transversal process, spinal process and pedicle looks good, no narrowing on cervical intervertebral discs, normal retropharyngeal and retrotracheal space.

## DISCUSSION

Obesity is defined as an excess of body fat.<sup>8,9</sup> It is a complex disorder, involves both genetic and environmental influences.<sup>10</sup> The mechanism of obesity development is not fully understood and it is believed to be a disorder with multiple causes.<sup>11</sup> The International Obesity Task Force (IOTF) use body mass index (BMI; weight in kilograms divided by height in meters squared ( $\text{kg}/\text{m}^2$ )) to assess obesity in children and adolescents.<sup>8,9</sup> BMI is a useful measure of adiposity because it accounts for variations in height.<sup>12</sup>

In this patients an 11-year-old boy with weight 83.3 kg and height 142 cm, we found her Body Mass Index (BMI) was 41 which makes us diagnose this patient with obesity. Causes of obesity in this patients were multifactorial involving both genetic and environmental

factors which increase the portion of dietary and reduced physical activity. We found parental BMI for father weight 95 Kg, height 176 cm was 30,7, 80<sup>th</sup> percentile and mother weight 65 Kg, height 155 cm, BMI was 27,1, 50<sup>th</sup> percentile.

The management of obesity in children and adolescents must include preventive and treatment programs designed to support healthy diet and physical activity; nutrition education at all levels, in homes, schools, and canteens, must be associated with physical activities aimed at prevention and cure.<sup>8</sup> Currently, drugs are not considered safe and effective for all ages and should be reserved for cases that do not respond to behavioral treatments.<sup>9</sup>

Most prevention programs include at least one of the following components: dietary changes, physical activity, behavior and social modifications, and family participation. Physical activity interventions have recently focused more on reducing inactive time, particularly television viewing. Results from recent studies have reported success in reducing excess weight gain in preadolescents by restricting TV viewing.<sup>13</sup>

We provide nutritional education for weight loss intervention, we enhance children's knowledge about diet, physical activity, and health, and promote their self-efficacy for healthful behaviors. We do not gave therapeutic drugs.

Based on the National Cholesterol Education Program (NCEP) recommendation that initial step to reduce cholesterol levels in children is the institution of a "heart-healthy" dietone that is low in cholesterol and saturated fat and high in complex carbohydrates, and provides adequate energy for growth and the maintenance of a desirable weight.<sup>14</sup> The initial approach is to use the NCEP step I diet. In a step I diet, no more than 30 percent of total calories come from fat, less than 10 percent of total calories come from saturated fat and dietary cholesterol is restricted to 100 mg per 1,000 kcal, not to exceed 300 mg per day.<sup>23</sup> Goal for children and adolescents with a high level of LDL cholesterol is to reduce the level to lower than 130 mg per dL (3.35 mmol per L). To confirm the effectiveness of dietary changes, the LDL cholesterol level should be checked three to six months after treatment is started and yearly thereafter.<sup>14</sup>

The boy was given diet based on step I diet the National Cholesterol Education Program (NCEP) recommendations for a eleven-year-old consisted of total calories 1930 kcal, total fat 579 kcal (64 g), saturated fat 193 kcal (21 g).

Careful anthropometric measurements and regular monitoring of selected obesity-associated complications using some or all of the following tests: fasting blood tests (glucose, insulin, lipids, liver function tests), blood pressure measurement, glucose tolerance test, liver ultrasound, measurements of psychosocial functioning, lung function tests, and biomechanical or pediatric assessment.<sup>8</sup>

We found psychosocial dysfunctions, isolation, depression, and low self-esteem as early consequences of obesity in our patient, whereas cardiovascular risk factors we found dilated right ventricle and severe hypertension. Pediatric obstructive sleep apnea (OSA) is defined by the American Thoracic Society (ATS) as a disorder of breathing during sleep characterized by prolonged partial upper airway obstruction and/or intermittent complete obstruction (obstructive apnea) that disrupts normal ventilation during sleep and normal sleep patterns, neurocognitive deficits, and cardiovascular morbidities.<sup>15,16</sup> Symptoms include habitual (nightly) snoring (often with intermittent pauses, snorts, or gasps), disturbed sleep, and daytime sleepiness, daytime neurobehavioral problems.<sup>17,18</sup> Some studies supported the role of genetic mechanisms in the etiology of OSA, but in whom adenotonsillar hypertrophy is considered to be the main causative factor for OSA, the role of inheritance is unclear.<sup>19</sup> Nocturnal sleep laboratorybased PSG is considered the gold standard for the diagnosis and assessment of OSA in children and is defined as testing that includes cardiorespiratory monitoring, as well as electroencephalographic (EEG), electrooculographic, and electromyographic monitoring (EMG).<sup>20</sup> On the basis of the relative contributions to the pathophysiology of OSA by adenotonsillar hypertrophy and increased fat deposits in the upper airway structures, two distinct types of OSA exist in children, one associated with marked lymphadenoid hypertrophy in the absence of obesity (type I), and the other associated primarily with obesity and with milder upper airway lymphadenoid hyperplasia (type II).<sup>18</sup> In this context OSA type III would address to a variety of craniofacial and neuromuscular disorders.<sup>18</sup>

Diagnosis of OSA in these patients was based on clinical suspicion, history, and physical findings, an overnight sleep study polysomnography (PSG) as gold standard for diagnosing sleep apnea can not be done in Kariadi Hospital due to unavailability of equipment. We found all the symptoms that lead us to the diagnosis of pediatric OSA. Patients have multiple risk factors for the occurrence of OSA among which are adenotonsillar hypertrophy, obesity and male sex. And genetically patients had both parents who are also obese, but do not experience tonsil hypertrophy and no symptoms of OSA. The boy already diagnosed with tonsillar hypertrophy since age 5 years, and during the course of their illness patients experience worsening and recommended for surgery. From clinical symptoms the patients are more leads to type 2 of OSA. The patient tonsil size was grade 4 therefore we can diagnose as tonsillar hypertrophy. The patient adenoid size was 0.714 (normal A/N ratio for 11.6–12.6 years age was  $0.532 \pm 0.1401$  SD –  $0.518 \pm 0.1542$  SD) therefore we can diagnose as adenoid hypertrophy.

The recommended initial treatment, even in obese children, consists of surgical removal of the adenoids and

tonsils.<sup>5,6</sup> Several studies have shown that adenotonsillectomy reverses the symptoms and confirm the beneficial effects for OSA on children's growth, school performance, improvements in PSG, behavior, QoL and cardiac function.<sup>5-7</sup> Because physicians have increasing awareness of neurocognitive deficits associated with OSA treated later in childhood, more children are now undergoing adenotonsillectomy at a younger age.<sup>5</sup> However, not all children who undergo adenotonsillectomy for OSA are cured.<sup>5</sup> The success rate for adenotonsillectomy in the context of OSA was approximately 85%.<sup>6</sup> Postoperative respiratory complications have been reported to occur in 5% to 25% of children with OSA undergoing an adenotonsillectomy.<sup>5</sup> These complications include oxygen desaturation, atelectasis, pneumonia, pulmonary edema, pleural effusion, pneumothorax or pneumomediastinum, and upper airway obstruction manifested as inspiratory stridor with increased work of breathing.<sup>7</sup> In this patient we have done adenotonsilectomy for the initial treatment. We found inspiratory stridor as postoperative complications that might be caused of inflammatory edema, for that we have given the boy antibiotic and corticosteroid.

Dexamethasone has been shown to reduce postoperative discomfort, improve dietary tolerance, and almost eliminate postoperative emesis, by reducing the inflammation in the oropharynx.<sup>5,6</sup>

Untreated OSA can result in serious morbidity.<sup>17</sup> The major consequences of pediatric OSA involve the central nervous system (CNS), neurobehavioral, cardiovascular and endocrine, metabolic systems and somatic growth, ultimately leading to reduced quality of life.<sup>17,18</sup>

In neurobehavioral, we found impairments in daily functioning that make decrease quality of life because of OSA symptoms. We found the boy poorly at school, that make the boy repeated 1 grade of class in his school. He had daytime sleepiness, hyperactivity, and aggressive behaviors. In this case the parents reported that the boy had excessive daytime sleepiness. Results of blood sugar within normal limits, but we have not examined further in to the possibility of peripheral insulin resistance by measuring levels of insulin in the blood or glucose tolerance test. From the results of lipid levels we found high levels of LDL cholesterol, high normal limit for triglycerides, low normal for HDL cholesterol. The consequences of untreated OSA have been occurred in our patients which has occurred cardiovascular disturbance with dilatated right heart ventricle and systemic hypertension.

Pediatric OSA has been now associated with a higher risk for cardiovascular morbidities.<sup>21,22</sup> Increased prevalence of altered blood pressure regulation, systemic hypertension, and changes in left ventricular geometry have all now been reported in children with OSA.<sup>23,24</sup>

The cumulative evidence indicates that both OSA and obesity lead to significant decreases in quality of life in a large proportion of children, particularly when both obesity and OSA coincide.<sup>1,3</sup> It is also likely that the sleep disturbance associated with OSA will increase fatigue and lead to increased irritability, depressed mood, impaired concentration, and decreased interest in daily activities, and that these impairments in daily functioning may in turn interfere with other aspects of the child's life, including relationships with family, school, and peers.<sup>1,3</sup>

### CONCLUSION

Adenotonsillectomy and weight reduction is considered to be the primary intervention for OSAS children. Because the case had also severe hypertension, antihypertensive and other supportive medicine were give and had a good result.

### REFERENCES

1. Arens R, Muzumdar H. Childhood obesity and obstructive sleep apnea syndrome. *J Appl Physiol* 2010;108:436-44.
2. Cheung JMY, Leung S, Chow P, Kwok K, Lam Y, Chan E, et al. The correlation among obesity, apnea-hypopnea index, and tonsil size in children. *Chest* 2006;130:1751-6
3. Verhulst SL, Aerts L, Jacobs S. Sleep-disordered breathing, obesity, and airway inflammation in children and adolescents. *Chest* 2008;134:1169-75
4. Gozal D, Capdevila OS, Gozal LK. Metabolic alterations and systemic inflammation in obstructive sleep apnea among nonobese and obese prepubertal children. *Am J Respir Crit Care Med* 2008;177:1142-9
5. Shine NP, Lannigan FJ, HL Coates, Wilson A. Adenotonsillectomy for Obstructive Sleep Apnea in Obese Children : Effects on Respiratory Parameters and Clinical Outcome. *Arch Otolaryngol Head Neck Surg.* 2006;132:1123-7
6. Statham MM, Elluru RG, Buncher R, Kalra M. Adenotonsillectomy for obstructive sleep apnea syndrome in young children : prevalence of pulmonary complications. *Arch Otolaryngol Head Neck Surg* 2006;132:476-80
7. Ye J, Liu H, Zhang G, Li P, Yang Q, et al. Outcome of Adenotonsillectomy for obstructive sleep apnea syndrome in children. *Annals of Otolaryngology & Laryngology* 2010; 119(8):506-513.
8. Fisberg M, Baur L, Chen W, Hoppin A, Koletzko B, Lau D, et al. Obesity in children and adolescents: working group report of the second world congress of pediatric gastroenterology, hepatology, and nutrition. *J Pediatr Gastroenterol Nutr* 2004 ; 39(2)
9. Dehghan M, Danesh NA, Merchant AT. Childhood obesity, prevalence and prevention. *Nutrition Journal* 2005; 4:24
10. Marcie B, Schneider, Brill SR. Obesity in children and adolescents. *Pediatr. Rev* 2005; 26; 155-162
11. Miller J, Rosenbloom A, Silverstein J. Childhood obesity. *Clin. Endocrinol. Metab* 2004; 89: 4211-8
12. Benson L, Baer HJ, Kaelber DC. Trends in the diagnosis of overweight and obesity in children and adolescents : 1999-2007. *Pediatrics* 2009; 123; 153-8
13. Caballero B. Obesity Prevention In Children : Opportunities And Challenges. *International Journal of Obesity* 2004; 28:S90-5
14. Shamir R, Fisher EA. Dietary Therapy For Children With Hypercholesterolemia. *Am Fam Physician* 2000; 61(3):675-82
15. Lumeng JC, Chervin RD. Epidemiology of pediatric obstructive sleep apnea. *Proc Am Thorac Soc* 2008; 5: 242-52
16. Muzumdar H, Arens R. Diagnostic issues in pediatric obstructive sleep apnea. *Proc Am Thorac Soc* 2008; 5: 263-73
17. Schechter MS. Technical report: diagnosis and management of childhood obstructive sleep apnea syndrome. *Pediatrics* 2002;109(69)
18. Capdevila OS, Gozal LK, Dayyat E, Gozal D. Pediatric obstructive sleep apnea complications, management, and long-term outcomes. *Proc Am Thorac Soc Vol 5.* pp 274282, 2008
19. Ovchinsky A, Rao M, Lotwin I, Goldstein NA. The Familial Aggregation of Pediatric Obstructive Sleep Apnea Syndrome. *Arch Otolaryngol Head Neck Surg* 2002;128:815-8
20. Spriggs WH. *Essentials of Polysomnography : A Training Guide and Reference For Sleep Technicians.* Jones And Bartlett Publishers. 2010
21. Parati G, Lombardi C, Narkiewicz K. Sleep apnea: epidemiology, pathophysiology, and relation to cardiovascular risk. *Am J Physiol Regul Integr Comp Physiol* 2007; 293: 1671-83
22. McNicholas WT, Bonsignore MR. Sleep apnoea as an independent risk factor for cardiovascular disease: current evidence, basic mechanisms and research priorities. *Eur Respir J* 2007; 29: 156-78
23. Garvey JF, Taylor CT, McNicholas WT. Cardiovascular disease in obstructive sleep apnoea syndrome: the role of intermittent hypoxia and inflammation. *Eur Respir J* 2009; 33: 1195-205
24. Vanhecke TE, Franklin BA, Zalesin KC, Sangal RB, DeJong AT, Agrawal, McCullough PA. Cardiorespiratory fitness and obstructive sleep apnea syndrome in morbidly obese patients. *Chest* 2008; 134:539-45