



Original Article

The Correlation Between Bullous Concha Volume and Type of Nasal Septal Deviation with Lund-Mackay CT Score in Chronic Rhinosinusitis

Monica Cherlady Anastasia¹, Anna Mailasari Kusuma Dewi², Farah Hendara Ningrum¹

¹Department of Radiology Faculty of Medicine Diponegoro University / Kariadi Hospital Semarang, Indonesia

²Department of Ear, Nose, and Throat Clinic, Faculty of Medicine Diponegoro University / Kariadi Hospital Semarang, Indonesia

Abstract

p-ISSN: 2301-4369 e-ISSN: 2685-7898
<https://doi.org/10.36408/mhjcm.v9i3.800>

Accepted : August 15th, 2022

Approved : November 11th, 2022

Author Affiliation :

Department of Ear, Nose, and Throat Clinic,
Faculty of Medicine Diponegoro University /
Kariadi Hospital Semarang,
Indonesia

Author Correspondence :

Anna Mailasari Kusuma Dewi
Dr. Sutomo Street No. 16 Semarang,
Central Java 50244, Indonesia

E-mail :

anna_drtht@fk.undip.ac.id

Background : Chronic rhinosinusitis is inflammation of the mucoperiosteum lining of the nose and paranasal sinuses for more than 12 weeks. Computed Tomography (CT scan) of the paranasal sinuses is the gold standard for diagnosing chronic rhinosinusitis. Nasal septal deviation and bullous concha are anatomical variation that often found in CT scan of chronic rhinosinusitis patients. The severity of chronic rhinosinusitis can be evaluated with Lund Mackay CT score. This study was aimed to analyse the correlation between bullous concha volume and type of nasal septum deviation with Lund-Mackay CT Score in chronic rhinosinusitis.

Methods : This was an observational study with a cross sectional design. This study was conducted from March-May 2019. Subjects were CRS patients whom underwent paranasal sinuses CT scan in Dr. Kariadi Hospital Semarang whom met the criteria. The inclusion criteria were chronic rhinosinusitis patients more than 17 years old with deviated nasal septum and conchae bullosa.

Results : There were 50 CRS patients, the age average is 18–67 years. The mean volume of the bullous concha was 0.534 cm³. The highest deviation of the nasal septum is to the right (53.2%) and the highest total Lund-Mackay CT Score was 4 (56%). There is no significant correlation between the volume of the bullous concha and the type of septal deviation with Lund-Mackay CT score.

Conclusion : Lund Mackay CT score didn't correlate with septal type and bullous concha volume.

Keywords : Bullous Concha, Chronic Rhinosinusitis, Lund Mackay CT score, Nasal Septum Deviation

INTRODUCTION

Rhinosinusitis is an inflammation of the mucoperiosteum lining of the nose and paranasal sinuses. The Task Force for Rhinosinusitis of the American Academy of Otolaryngology classifies rhinosinusitis according to the length of the disease course, where acute rhinosinusitis is rhinosinusitis lasting less than 4 weeks, subacute rhinosinusitis lasting 4 to 12 weeks and chronic rhinosinusitis if it has lasted more than 12 weeks. Based on data from the EP3OS (European Position Paper on Rhinosinusitis and Nasal Polyps) in 2012, rhinosinusitis has a prevalence that varies in several countries, with the prevalence of rhinosinusitis in America being 15.5–16%, in Korea 1.01%, in Belgium 6%, in Scotland 9.6%, and in the Caribbean 9.3%.^{1,2} Meanwhile, according to the European Rhinology Society, chronic rhinosinusitis has a prevalence of 10.9% in Europe at the age of 15–75 years. According to data from the Institute of Medical Statistics in 2002, the diagnosis of rhinosinusitis was found in 2.2 million patients in Germany.³ In a study in Indonesia, among 30 chronic maxillary rhinosinusitis patients there were 15 patients with positive fungal culture results (50%), and most of them were aged 37–46, and male more than female (9:5).⁴

Nasal septal deviation is the most common finding of anatomical variations from CT scan chronic rhinosinusitis patients (74.8%).⁵ The prevalence of deviated nasal septum with convexity to the right is 51% and convexity to the left is 49%.⁶ Study in Turkey shows the magnitude of the angle of deviation Nasal septum ranged from 4.9–34.1 degree.⁷ Bullous conchae were found in 33.8–72.6% of rhinosinusitis patients. Study in India found that there was no difference incidence bullous concha in male (43.47%) and female patients (47.06%). Concha bullosa causes narrowing of the middle meatus that cause obstruction of the osteomeatal complex. This obstruction affects the ventilation of the paranasal sinuses and mucociliary transport in the middle meatus area causing maxillary and ethmoidal sinusitis. Computerized Tomography examination (CT scan) of the paranasal sinuses is the gold standard examination for diagnosing chronic rhinosinusitis. CT scan of the paranasal sinuses has high sensitivity (93–100%) and specificity (86–95%) in assessing abnormalities in the paranasal sinuses. The Lund Mackay CT score provides a rhinosinusitis staging system using radiological scoring that is effective in evaluating and communicating the severity of rhinosinusitis to other specialists.^{1,6,8,9}

The purpose of this study is to assess the correlation between the volume of conchae bullous and type of nasal septal deviation with the Lund Mackay CT score in chronic rhinosinusitis.

METHODS

This was an observational study with a cross sectional design. This study was conducted at the Diagnostic Radiology of the Dr. Kariadi Hospital Semarang, on March to May 2019. Subjects were chronic rhinosinusitis patients who underwent paranasal sinuses CT scan without contrast at the Radiology Department in Dr. Kariadi Hospital Semarang. The sampling method used consecutive sampling, with inclusion criteria were patients more than 17 years with deviated nasal septum and conchae bullosa. Patients with sinonasal neoplasms, previous paranasal sinus surgery, and maxillofacial trauma were excluded. The volume of the conchae bullosa was assessed using anteroposterior, laterolateral and craniocaudal distance measurement techniques in a linear manner on coronal and sagittal sections. Each pneumatization of bullosa concha was measured by the formula: height x width x anteroposterior diameter x 0.52. We used Mladina classification to classified nasal septal deviation. The severity of chronic rhinosinusitis was assessed used Lund Mackay CT score with maximum score was 24. The assessments for each right and left sinus: score 0 no abnormality, score 1 partial opacity, and score 2 total opacities. The assessments for each right and left osteomeatal complex: score 0 no obstruction and 2 positive obstructions.

The data was shown with table or graphic. Kolmogorov-Smirnov and Shapiro Wilk test used for normality test. The correlation statistical analytic tests using the Rank Spearman, Kruskal Wallis and one way anova correlation tests. Significant correlation the test results $p < 0.05$, it means that it has a and is strengthened by the correlation coefficient.

This study was conducted after obtaining permission from the Health Research Ethics Commission and the Medical Council of Dr. Kariadi Hospital Semarang No.131/EC/KEPK-RSDK/2019.

RESULTS

There are 50 subjects that meet the inclusion and exclusion criteria. The incidence based on age group are under 20 years (16%), 21–30 years (18%), 31–40 years (20%), 41–50 years (24%), 51–60 years (12%), and over 60 years (10%). The youngest is 18 years and the oldest is 67 years, with the highest age group at the age of 41–50 years (24%). Most of the subjects were female (54%). In this study we found 64 pieces of bullous concha and mostly in the right side (54.7%). Only 30% subjects with bilateral bullous concha and mostly unilateral bullous concha (70%).

The volume of bullous concha was assess using volumetric CT software from non-contrast paranasal sinus MSCT data and measure in cubic centimetres (cm³). The volume of bullous conchae in this study had highly

TABLE 1
Mean volume bullosa concha based on the type of bullosa concha

Type of Bullosa Concha	N (%)	Mean of Volume
Lamellar	34 (53.1%)	0.496
Extensive	19 (29.7%)	0.538
Bulbosa	11 (17.2%)	0.647
Total	64 (100%)	

TABLE 2
The characteristics deviation nasal septum with Mladina classification

Mladina classification	Deviation type	Total	Percentage (%)
Type I	Midline septum	20	31.3
Type II	Anterior vertical C shape	18	28.1
Type III	Posterior vertical C shape	2	3.1
Type IV	S shape	6	9.4
Type V	Horizontal spur	14	21.9
Type VI	Horizontal spur with groove	1	1.6
Type VII	Combination	3	4.7

TABLE 3
Patient characteristics based on Lund-Mackay CT Score

Lund Mackay Score	Total	Percentage (%)
1	24	37.5
2	26	40.6
3	7	10.9
4	2	3.1
5	3	4.7
6	1	1.6
7	1	1.6

variable values from 0.27 cm³ to 1.05 cm³, with the median is 0.52 cm³ and the mean \pm SD is 0,54 \pm 0,19 cm³. Lamellar type was found more common than others. The mean volume of the bullous concha based on the type of pneumatization is in table 1.

The type of the nasal septal deviation based on the Mladina classification. The characteristic of nasal septal deviation is shown in table 2. Mostly deviation to the right 53.2% with the most common type were type I Mladina (31.3%) and type II Mladina (28.1%). Subject with unilateral bullous concha and contralateral deviated

nasal septal was 56.4%, while the unilateral bullous concha with ipsilateral deviated nasal septum was 43.6%.

Among the total results of the Lund-Mackay CT score, 6 (12 %) had high score (score > 8), 16 (32%) had moderate score (score 5-7), and 28 (56%) had low scores (scores < 4). The range of the unilateral side Lund-Mackay CT score was 1-7, with the average \pm SD 2,06 \pm 1,30 and the description is shown in table 3. The distribution of Lund-Mackay CT Score based on sinus location is in figure 1.

The normality test result with Kolmogorov-

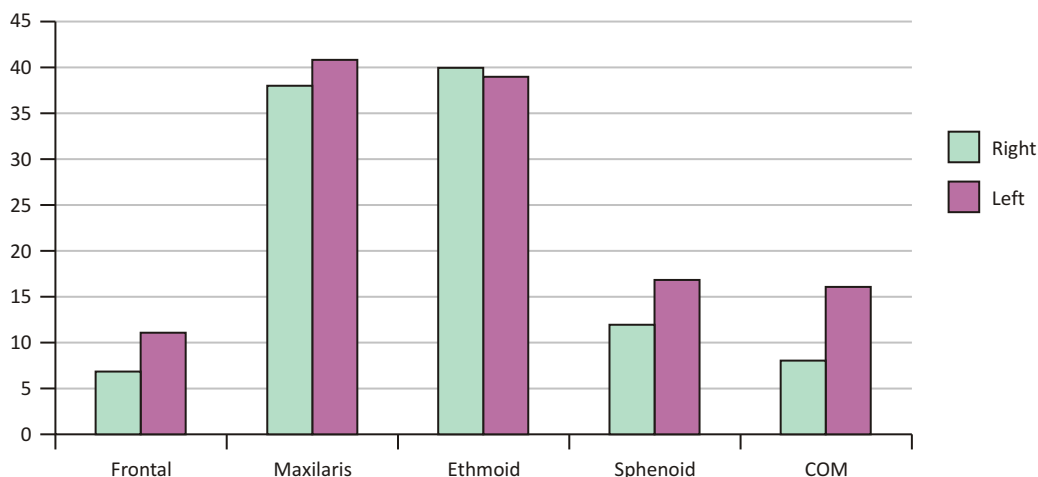


Figure 1. Distribution of Lund-Mackay CT Score based on right and left unilateral sinus location

TABLE 4

The correlation between the volume of bullous concha and the Lund-Mackay CT score

Variable	p	r
Volume of bullous concha	0.784	- 0.035
Lund-Mackay CT score		

Spearman's correlation test, signifikan $p < 0.05$

TABLE 5

The correlation between the type of septal deviation and the Lund-Mackay CT score

Type septum	Lund-Mackay CT score	p
Type I	2 (1-5)	0.383
Type II	2 (1-7)	
Type III	1 (1-5)	
Type IV	2 (1-2)	
Type V	2 (1-6)	
Type VI	2	
Type VII	2	

Kruskal Wallis correlation test, signifikan $p < 0.05$

Smirnov test showed that the distribution data of the volume bullous concha was normal ($p > 0.200$) and the Lund Mackay CT score was not normal ($p < 0.00$). The analysis continued with the Spearman's correlation test (table 4). The correlation test results of Spearman's volume of bullous concha to Lund-Mackay CT score obtained p value = 0.784 and $r = -0.035$, because p value > 0.05 , it can be concluded that the volume of bullous concha to Lund-Mackay CT score has no significant correlation.

The Shapiro-Wilk Lund-Mackay CT score normality test based on the type of septum found that the data distribution was not normal, so the Kruskal Wallis test was used for the next step (Table 5). From the results of the Kruskal Wallis Lund-Mackay CT score test based on Septum type showed p value > 0.05 , it can be concluded that there was no significant correlation between septum type and Lund-Mackay CT score.

The Shapiro-Wilk normality test for the volume of the bullous concha based on the type of septum, it was

TABLE 6
The correlation between the type of septal deviation and the bullous concha volume

Type septum	Bullous concha volume	p	Levene
Type I	0.54 ± 0.18	0.145	0.544
Type II	0.51 ± 0.15		
Type III	0.69 ± 0.27		
Type IV	0.70 ± 0.29		
Type V	0.48 ± 0.17		
Type VI	0.29		
Type VII	0.53		

One way anova correlation test, signifikan $p < 0.05$

found that the data distribution was normal. There was no significant relationship between bullous conchae volume and septal type (p value = 0.145 and levene = 0.544).

DISCUSSION

The are high variation in prevalence of chronic rhinosinusitis, data from self reported physician shows 5,5% in Brazil to 28% in Iran.¹ The prevalence in the U.S. range from 2.1% to 13.8%, in Europe 6.9% to 27.1%, in China 4.8% to 9.7%, in a Canadian population 2.3–2.7 per 1000 population and in Pennsylvania 1048±48 per 100.000 person-years.¹⁹ Based on data from the European Position Paper on Rhinosinusitis and Nasal Polyps the overall prevalence of chronic rhinosinusitis is 10.9% and in women is more than man. Age is associated with the incidence of chronic rhinosinusitis, in the adult group the incidence increases with age, 2.7% in the 20–29 year age group and 6.6% in the 50–59 year age group. In the elderly the prevalence of chronic rhinosinusitis is decreased to 4.7%.¹ However, in our study we found in the young adult group, females are equal with males, 27 women (54%) and 23 men (46%). This study found that the highest incidence rate is the 41–50 years age groups (24%), and decreased in the fifth and sixth decades.

Lund-Mackay CT score is common to evaluate the severity of chronic rhinosinusitis. In a multicentre prospective study of CRS patients undergoing surgery there was correlation with Lund-Mackay CT score, this study shows the higher the score linier with the higher the grade of polyp and the more extensive the surgery.¹⁹ Based on Chen's research, it was found that the total bilateral Lund Mackay CT Score was more than 5, while the unilateral Lund Mackay CT Score was more than 4.¹¹ In this study, some samples of chronic rhinosinusitis were in the low Lund-Mackay CT Score category (56%) with a low score of 56%. The lowest unilateral Lund-Mackay CT

Score was 1 (29.6%), while the highest unilateral Lund Mackay CT Score was 7 (4.3%). Previous study tested the accuracy of CT in the diagnosis of CRS including a control group without CRS, they compare CT scores with histopathologic grade of inflammation. By using the ROC method, the sensitivity of CT was found to be 94% and specificity 41% using an Lund-Mackay CT score cut-off value for CRS of greater than 2. If the value of "normal" LMS scores (i.e. >4) was applied, specificity increased to 59%. Using the same method in paediatric rhinosinusitis, taking an Lund-Mackay CT score of at least 5 to indicate real disease, CT sensitivity was 86% and specificity 85% (546). Thus, an Lund-Mackay CT score of 2 or less has an excellent negative predictive value, and an Lund-Mackay CT score of five or more has an excellent positive predictive value, strongly indicating true disease.¹⁹

Anatomical variations that can cause chronic rhinosinusitis include bullous concha and nasal septal deviation. Patients with a concha bullosa had increased Lund-Mackay scores for maxillary sinuses only. In another surgical study, Qualliotine et al, found that patients with concha bullosa had worsened quality of life scores and improved more after surgery than patients without that specific anatomic abnormality.¹⁹ Concha bullosa can occur unilaterally or bilaterally. In this study we found 64 concha bullosa from 50 patients, and mostly unilateral (70%). Among these subjects, the concha bullous commonly in the right side (53.1%) and the most type of bullous is lamellar (53.1%). There is high variation in prevalence of concha bullosa in chronic rhinosinusitis patients. Tuncyurek showed there are 42.6% conchae bullosa in patients with chronic rhinosinusitis, 33.3% are unilateral on the right side, 25.9% are unilateral conchae bullous on the left side, 16.7 % are bilateral and most of them are lamellar type (25.3%). This study is similar with our study, the most common type of bullous concha is lamellar type and mostly unilateral on the right side.⁷

The range of concha bullous volume in this study

is wide, between 0.27 cm³ to 1.05 cm³, with the median is 0.52 cm³ and the average is 0.534 cm³. The average volume based on the type bullous concha are: the lamellar type 0.496 cm³, bulbous type 0.647 cm³, and extensive type 0.538 cm³. The results from Karatas study shows the average volume of bullous concha was 1.07 cm³ at the age of 19–33 years and the volume was 1.13 cm³ at the age of 34–70 years.¹⁰ In this study, the average volume of bullous concha at the age of 19–33 years was 0.534 cm³ and 0.533 cm³ at the age of 34–70 years.

This study result found that there is no correlation between the volume of the bullous conchae with the Lund-Mackay CT Score ($p = 0.647$). This indicates that an increase in the volume of the bullous conchae was not followed by an increase in the Lund-Mackay CT Score. In the Karatas study, there was a moderate correlation between the volume of the bullous conchae and maxillary sinusitis.¹⁰ The difference between the Karatas study and this study was that the previous study only assessed the maxillary sinus, whereas in this study all unilateral paranasal sinuses were assessed.^{12,13} Systematic review from International Consensus Statement on Allergy and Rhinology: Rhinosinusitis (ICAR-RS) concluded there is literature both supporting and refuting an association between anatomic variations and CRSsNP. The articles demonstrating an association show a generally small effect with some contribution of anatomic variation in the pathogenesis of CRSsNP. In contrast for CRSwNP there is less correlation with anatomic variation, due to reason that most of the studies suggest that pathophysiology of the CRSwNP is a diffuse disease process.¹⁹ The insignificant correlation between the volume of the conchae bullosa and the Lund-Mackay CT score can be explained as the unilateral sinonasal disease is not only caused by the conchae bullosa but can also be caused by other factors such as inflammation or obstruction due to mass of the osteomeatal complex that can interfere the mucociliary transport in paranasal sinuses. Based on the pathophysiology, conchae bullosa and deviated septum can obstruct the middle meatus, which is the estuary of the 3 anterior sinuses: maxillary sinus, anterior ethmoid sinus, and frontal sinus. While the posterior ethmoid sinus and sphenoid sinus ends in the superior meatus.^{12,13} This is in accordance with this study where the average of the largest Lund Mackay Score increased in the maxillary and ethmoid sinuses.

Nasal septal deviation based on Mladina's criteria is divided into 7 types: types I, II, III, IV, V, VI, and VII.¹⁴ Rehman found there is a relationship between the type of nasal septum and the ridge (type VI) and the presence of a spur (type V) against ipsilateral sinus disease. Meanwhile, nasal septal deviation types I and II rarely cause sinonasal disease.¹⁵ Our study found that the most common types of nasal septal deviation based on Mladina's classification were type I (31.3%) and type II (28.1%), while the type VI of nasal septal deviation was

rare (1.6%). In contrast to the results in this study, the most common types of nasal septal deviation were type I and type II. This is probably because the patient at Dr. Kariadi Hospital has a main complaint of nasal congestion that related with type I and II nasal septal deviation.

This study found 56.4% unilateral turbinate bullosa with contralateral deviated septum. It is similar with Bhandari's study where the prevalence of unilateral concha bullous with contralateral deviated septum was 87.5%. However, in this study, it was stated that there was still a gap between the medial aspect of the dominant turbinate and the surface of the nasal septum so that the septal deviation to the contralateral side was not caused by propulsion of the nasal turbinate.¹⁶

The correlation test between the deviated septum type and the Lund-Mackay CT Score with $p = 0.344$ showed that there was no correlation between the deviated septal type and the Lund-Mackay CT Score. In Rao's study, stated that the most common types of nasal septal deviation associated with chronic sinusitis were types III, V, and VI.¹⁷ In contrast to this study, the most common types of nasal septal deviation were types I and II. This is because most of the patients are in the category of low Lund Mackay CT Score (56%) and the variation in the type of deviation of the nasal septum is less evenly distributed. The other difference is the previous study was compared to the control group, while this study was not compared to the control group.

This study assessed the correlation test between the type of deviated septum and the volume of the conchae bullosa ($p=0.142$). In Smith's study, it was stated that the presence of nasal septal deviation is generally associated with a dominant or large turbinate.¹⁸ However, in Bhandari's study, the deviation of the septum to the contralateral side was not caused by pushing the nasal septum.¹⁶ In this study, the varying types of septal deviation did not affect the volume of the turbinate bullosa, this is probably because the turbinate bullosa only affected type III nasal septal deviation (which is located near from the middle meatus), and types V and VI (which are more laterally located and cause compression of the lateral nasal wall).

The results showed that there was no significant correlation between the type of concha bullosa and the Lund-Mackay CT Score ($p=0.667$). The existence of different types of turbinate bullosa did not affect the severity of rhinosinusitis. Pathophysiologically, the bullous concha can obstruct the middle meatus which causes sinusitis, this can be caused by various factors such as the size of the bullous turbinate or other anatomical factors in the complex osteomeatal region.

The other factors that might confound the correlation between the variables studied, including age and gender, but these two factors proved not to be confounders of the volume of the bullous conchae, the

type of deviation of the nasal septum and the Lund-Mackay CT Score.

In this study, we found less variation of the Lund Mackay CT score and the type of nasal septal deviation that can be limitation of this study.

CONCLUSION

There is no significant correlation between the volume of the bullous concha with the Lund-Mackay CT Score and between the type of septal deviation and the Lund-Mackay CT Score.

REFERENCES

1. Fokkens WJ, Lund VJ, Mullol J. European Position Paper on Rhinosinusitis and Nasal Polyps. Journal of the European and International Societies. Volume 50.2012
2. Thaler E, Kennedy D. *Rhinosinusitis: A Guide for Diagnosis and Management*. Springer Science and Business Media; 2009.
3. Access O. Epidemiology of chronic rhinosinusitis, selected risk factors, comorbidities, and economic burden. 2015;14 (Figure 1):1-31.
4. Indriany S, Munir D, Rambe AYM, Adnan A, Yunita R, Sarumpaet S. Proporsi karakteristik penderita rinosinusitis kronis dengan kultur jamur positif. *Oto Rhino Laryngol Indones*. 2016;46(1):26-35. <http://www.orli.or.id/index.php/orli/article/view/144/128>.
5. Sarkar PS, Bhosale PR, Bharthi AR, Ananthasivan R. Computed Tomography Scan Correlation between Anatomic Variations of Paranasal Sinuses and Chronic Rhinosinusitis. 2016;4(4): 122-128. doi:10.17354/ijss/2016/389.
6. Bahemmat N, Hadian H. The frequency of nasal septal deviation and concha bullosa and their relationship with maxillary sinusitis based on CBCT finding. 2016:152-156.
7. Tuncyürek Ö. The relationship among concha bullosa, septal deviation and chronic rhinosinusitis. *J Med Updat*. 2013;3(1):1-7. doi:10.2399/jmu.2013001002.
8. Mundra RK, Gupta Y, Sinha R, Gupta A. CT Scan Study of Influence of Septal Angle Deviation on Lateral Nasal Wall in Patients of Chronic Rhinosinusitis. *Indian J Otolaryngol Head Neck Surg*. 2014;66(2):187-190. doi:10.1007/s12070-014-0713-7.
9. Okushi T, Nakayama T, Morimoto S, et al. A modified Lund-Mackay system for radiological evaluation of chronic rhinosinusitis. *Auris Nasus Larynx*. 2013;40(6):548-553. doi:10.1016/j.anl.2013.04.010.
10. Karata D, Yüksel F, Koç A. Journal of the Anatomical Society of India Volumetric correlation between concha bullosa and paranasal sinuses. 2017:11-14. doi:10.1016/j.jasi.2017.05.011.
11. Chen JJ, Chen DL, Chen CJ. The Lund-Mackay score for adult head and neck computed tomography. *Chinese J Radiol*. 2011;36(4):203-208. doi:10.1177/0194599813496044a344.
12. Exhibit S, Serifoglu I, Oz II, et al. The effect of nasal septal deviation on nasal bone morphology: computed tomography evaluation. 2016:1-10.
13. Etigadda Y, Majeed J. Clinical and Radiological Evaluation of Deviated Nasal Septum in Classifying and Surgical Management of the Deviated Septums. 2017;16(2):13-20. doi:10.9790/0853-1602031320.
14. Mladina R, Skitarelić N, Poje G, Šubarić M. Clinical implications of nasal septal deformities. *Balkan Med J*. 2015;32(2):137-146. doi:10.5152/balkanmedj.2015.159957.
15. Rehman A. A Prospective Study of Nasal Septal Deformities in Kashmiri Population Attending a Tertiary Care Hospital. *Int J Otolaryngol Head Neck Surg*. 2012;1(3):77-84. doi:10.4236/ijohns.2012.13016.
16. Bhandary S, Kamath SD. Study of relationship of concha bullosa to nasal septal deviation and sinusitis. *Indian J Otolaryngol Head Neck Surg*. 2009;61:227-229
17. Rao JJ, Kumar ECV, Babu KR, Chowdary VS, Singh J, Rangamani SV. Classification of nasal septal deviations-Relation to sinonasal pathology. *Indian J Otolaryngol Head Neck Surg*. 2005;57(3):199-201. doi:10.1007/BF03008013.
18. Smith KD, Edwards PC, Saini TS, Norton NS. The Prevalence of Concha Bullosa and Nasal Septal Volumetric Tomography. 2010;2010:0-5. doi:10.1155/2010/404982.
19. Orlandi RR, Kingdom TT, Smith TL, et al. International consensus statement on allergy and rhinology: rhinosinusitis 2021. *Int Forum Allergy Rhinol*. 2021;11(3):213-739. doi:10.1002/alr.22741