



*Original Article*

## Correlation between Preoperative Osteitis Degree with Postoperative Endoscopic Score in Chronic Rhinosinusitis

Apriansah<sup>1</sup>, Anna Mailasari Kusuma Dewi<sup>2</sup>, Farah Hendara Ningrum<sup>1</sup>

<sup>1</sup>Department of Radiology, Faculty of Medicine Diponegoro University / Dr. Kariadi Hospital Semarang, Indonesia

<sup>2</sup>Department of Otorhinolaryngology - Head and Neck Surgery, Faculty of Medicine Diponegoro University / Dr. Kariadi Hospital Semarang, Indonesia

### Abstract

p-ISSN: 2301-4369 e-ISSN: 2685-7898  
<https://doi.org/10.36408/mhjcm.v10i1.784>

**Accepted:** July 26<sup>th</sup>, 2022  
**Approved:** January 12<sup>th</sup>, 2023

**Author Affiliation:**  
Department of Radiology,  
Faculty of Medicine Diponegoro University /  
Dr. Kariadi Hospital Semarang,  
Indonesia

**Author Correspondence:**  
Anna Mailasari Kusuma Dewi  
Dr. Sutomo Street No. 16 Semarang,  
Central Java 50244, Indonesia

**E-mail:**  
anna\_drtht@fk.undip.ac.id

**Background :** In chronic rhinosinusitis patients, there is a subgroup of patients with persistent symptoms after treatment, who often shows bone thickening and remodeling in their paranasal sinuses and described as osteitis. Osteitis can be evaluated by several methods, one of which is the Global Osteitis Score (GOS). This study was aimed to analyse the correlation between preoperative osteitis degree with the postoperative endoscopic scores in chronic rhinosinusitis.

**Methods :** It was an observational study with cross-sectional design. We use GOS from CT scan before surgery and Lund Mackay's endoscopic score 4 weeks after Functional Endoscopy Sinus Surgery (FESS). The analysis performed with Spearman correlation test.

**Results :** There were 30 patients as subjects. There statistical analysis test between preoperative osteitis degree with post operative endoscopic score showed  $p = 0.296$  with  $r = 0.197$ . The analysis result between risk factors for wound healing with the postoperative endoscopic score were allergic rhinitis ( $p = 1.000$ ), polyps ( $p = 0.624$ ), and smoking ( $p = 0.309$ ).

**Conclusion :** There is no significant correlation between preoperative osteitis degree with the postoperative endoscopic score, but there is a tendency for a positive correlation between preoperative osteitis degree with the postoperative endoscopic score. There was no significant correlation between allergic rhinitis, polyps, and smoking habits with postoperative endoscopic score.

**Keywords :** Osteitis, Endoscopic score, Chronic Rhinosinusitis, Global Osteitis Score, Lund Mackay endoscopic score

## INTRODUCTION

Chronic rhinosinusitis (CRS) is an inflammation of the nose and paranasal sinuses mucosa that lasts more than 12 weeks. There is a subgroup of CRS patients with persistent symptoms after treatment whose often shows thickening and remodeling in their paranasal sinuses bone, which are described as osteitis. Osteitis is one of the contributing factors in postoperative CRS recurrence.<sup>1</sup>

Computed Tomography scan (CT scan) is currently recognized as the gold standard in radiographic examinations for the diagnosis of CRS patients. CT Scan can describe the pathology and degree of rhinosinusitis and also a guiding for paranasal sinus anatomy before Functional Endoscopy Sinus Surgery (FESS).<sup>2</sup> There is no gold standard diagnostic for osteitis. However, paranasal sinus CT scan is commonly used to assessed the degree of osteitis by using the Global Osteitis Score (GOS).<sup>3</sup>

Rhinosinusitis is a clinical disorder that includes heterogeneous infections and inflammatory conditions affecting the paranasal sinuses. The American Academy of Otolaryngology-Head and Neck Surgery (AAO-HNS) defines chronic rhinosinusitis as sinusitis with clinical symptoms lasting more than 12 weeks. Recent research suggests that bones may play an active role in the CRS because the inflammation in CRS can spread through the Haversian system in the bones. The rate of bone change is the same as in osteitis of the paranasal sinuses in CRS. Furthermore, surgery that induces infection with either *Staphylococcus aureus* or *Pseudomonas aeruginosa* can induce osteitis and induce chronic inflammatory changes along the mucosa at a significant distance from the infection site. Therefore, osteitis may be an important factor in the spread of chronic inflammatory changes and may explain immunity to medical therapy.<sup>1,3</sup> Osteitis also plays a role in aggravating the degree of CRS and as a contributing factor to CRS recurrence after surgery.<sup>4-6</sup>

Osteitis can be diagnosed with histology and radiology examination and there were several scoring systems to examine osteitis. Although histology was considered the most accurate, but histology is more invasive because of the need for biopsy or surgery. CT

scan is less invasive and have several classifications to identify osteitis (Figure 1).<sup>3</sup>

The diagnosis of osteitis in CRS from CT scan based on the thickness of the bony partitions in the paranasal sinuses. A recent study modified on existing classification used bone thickness and bone involvement patterns in each sinus to calculate an entirety score, called the Global Osteitis Score (GOS). This method is the most widely used in assessing the degree of osteitis.<sup>3</sup>

Functional Endoscopy Sinus Surgery (FESS) is a major advancement in sinus surgery for the management of CRS. This type of surgery is preferred because it is a more effective and functional conservative measure.<sup>7</sup> The standard post-FESS therapy according to the clinical practice guidelines in Dr. Kariadi Semarang Hospital are oral antibiotics for 5-7 days (choice of Cephalosporins, Macrolides and Quinolones), coagulant agent, analgesics, corticosteroid and nasal saline irrigation. The endoscopic evaluation performed at the first, second, and four weeks after surgery. The wound healing process evaluate with endoscopic score. The Lund Mackay endoscopic score is the most common scoring, this system based on the degree of scar tissue, crusts, edema, polyps, and secretions.<sup>8</sup>

Wound healing influenced by local and systemic factors. Local factors are those that directly affect the characteristics of the wound. However systemic factors are the health conditions or individual diseases that affect the wound to heal, such as allergic rhinitis, nasal polyps, and smoking.<sup>9</sup> Patients with a history of allergic rhinitis can experience failure in postoperative wound healing due to persistent mucociliary dysfunction. Smoking can reduce wound healing process because nicotine interferes the oxygen supply to the tissues. Polyps has high recurrency therefore it can affect the outcome of surgery.<sup>10</sup>

The improvement CRS after surgery can be influenced by the degree of osteitis and systemic factors. Therefore, this study is to analyze the correlation between preoperative osteitis degree with the postoperative endoscopic scores in chronic rhinosinusitis.

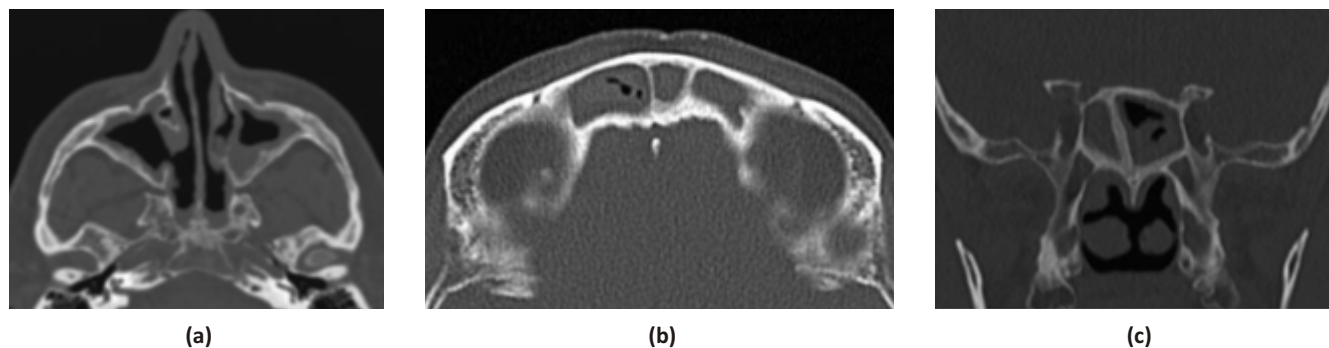

Figure 1. CT images of osteitis (a) maxillary, (b) sphenoid, and (c) frontal sinus.<sup>3</sup>

## METHODS

It was a retrospective observational study with a cross-sectional design, using secondary data from medical record. Subject was adult CRS patient who underwent FESS in Kariadi hospital. Patient with malignant tumor were excluded. We use sample estimation for test of significance of 1 correlation, with minimal sample was 30. The preoperative osteitis degree was analyzed using GOS and the endoscopic evaluation 4 weeks after surgery using Lund Mackay endoscopic score. The risk factor for endoscopic evaluation after surgery such as diabetic, smoking, allergic rhinitis and nasal polyp were examined.

Osteitis was defined as loss of bone definition/hyperostosis/new bone formation or signal heterogeneity overlying each sinus wall. The area of the maximal thickness of each osteitis focus was measured. The grading per sinus was as follows: Grade 1: The involvement of the sinus walls less than 50% and osteitis <3 mm in width. Grade 2: The involvement of the sinus walls less than 50% and osteitis 3–5 mm wide. Grade 3: The involvement of the sinus walls less than 50% and wider than 5 mm or the involvement of the sinus walls greater than 50% and osteitis <3 mm in width. Grade 4: The involvement of the sinus walls greater than 50% and osteitis 3–5 mm wide. Grade 5: The involvement of the sinus walls greater than 50% and osteitis < 5 mm.<sup>6</sup>

The Lund Mackay endoscopic scores assessed mucosal inflammation, discharge, scarring, and crusting in the maxillary sinuses, ethmoid sinuses, sphenoid sinuses, frontal sinuses, and olfactory fossa with values of 0–100 (Table 1).<sup>11</sup>

Data was analyzed with Spearman correlation test. The research data were processed using SPSS statistical software version 26. This research was conduct after received ethical approval from the Ethics Commission with the number 553/EC/KEPK-RSDK/2020.

## RESULTS

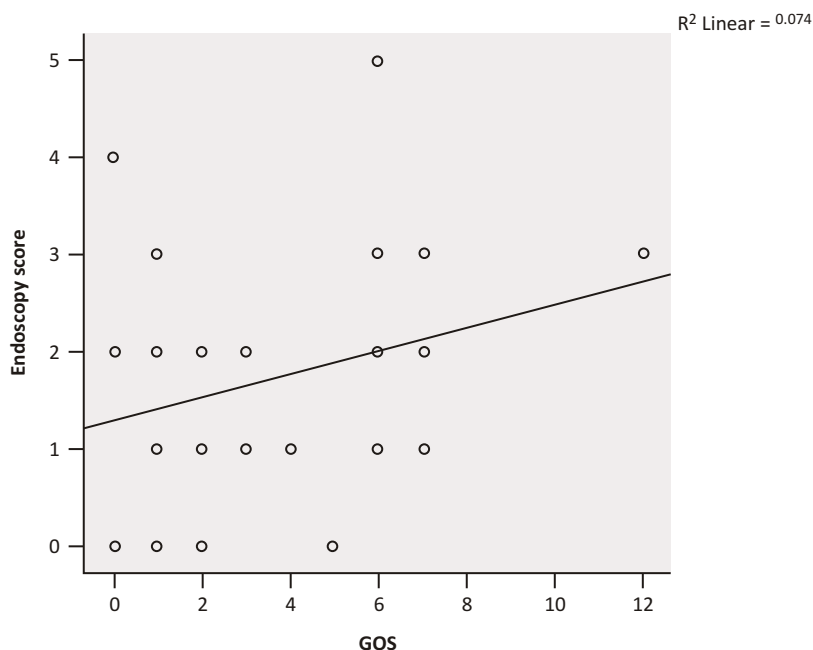
There were 30 adults patients, 18 to 57 years old. Male (57%) is often than female (43%). Preoperative osteitis degree shows the lowest score of GOS was 0 and the highest was 12, with mean score 3.27. The endoscopic evaluation 4 weeks after surgery shows the lowest Lund Mackay score of 0 and the highest 5, with mean score 1.67.

The result of the Spearman correlation test between preoperative osteitis degree (GOS) with endoscopic evaluation (Lund Mackay score) 4 weeks after surgery showed  $p=0.296$  ( $p>0.001$ ). However, the correlation was shown between the preoperative osteitis degree (GOS) with endoscopic evaluation (Lund Mackay score) 4 weeks after surgery had a positive tendency with  $r=0.197$  (Figure 2).

The risk factor for endoscopic evaluation after

**TABLE 1**  
**Lund Mackay Endoscopic Scoring System<sup>11</sup>**

Endoscopic scoring system	
Polyp	0 = absence of polyps, 1 = polyps only in middle meatus, 2 = polyps beyond middle meatus
Oedema	0 = absent, 1 = mild, 2 = severe
Discharge	0 = no discharge, 1 = clear, thin discharge, 2 = thick, purulent discharge
Eversion	0 = absent, 1 = mild, 2 = severe
Crusting	0 = absent, 1 = mild, 2 = severe



**Figure 2.** Correlation between preoperative osteitis degree (GOS) with endoscopic evaluation (Lund Mackay score) 4 weeks after surgery

TABLE 2

**The correlation of risk factor for endoscopic evaluation after surgery with the endoscopic evaluation (Lund Mackay score) 4 weeks after surgery**

Risk factors		Lund Mackay endoscopy score		p value
		Good	Not good	
Allergic Rhinitis	Yes	6	6	1,000*
	No	9	9	
Polyps	Yes	3	2	0,623**
	No	12	13	
Smoking	Yes	0	1	0,233**
	No	15	14	

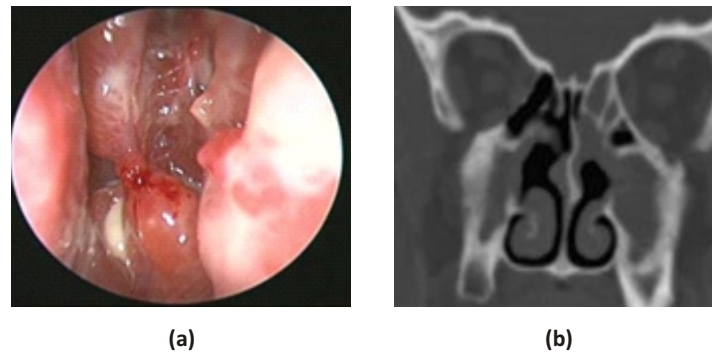
\*Chi square test, \*\* Fisher's test

surgery that found in this study was allergic rhinitis (12), smoking (1) and polyps (5). The results of the correlation of risk factor for endoscopic evaluation after surgery with the endoscopic evaluation (Lund Mackay score) 4 weeks after surgery showed  $p > 0.001$  (Table 2).

### DISCUSSION

The incidence of CRS is commonly found in adult. The lowest age of the subjects of this study was 18 years old, while the highest was 57 years old. Similar results from previous study in Kariadi Hospital (2019) reported that the incidence of CRS is at the age range of 18–55 years old.

It has been identified that in areas of persistent mucosal disease, the underlying bone degenerates and progressing to thickening and neo-osteogenesis. This further leads to increased mucosal scarring and potential for bone adhesion. Detailed histomorphometry and histology of the ethmoid bone in human patients were performed by Kennedy *et al.*<sup>3</sup> Their study shows the ethmoid bone involved in CRS was found to exhibit the same histomorphometry characteristics as well-described osteomyelitis conditions in other disciplines, especially chronic sclerosing osteomyelitis of the mandible. Resolution occurs only after debridement of the underlying soft bone and osteitis, before removal can



**Figure 3.** (a) Endoscopic view of acute exacerbation of chronic rhinosinusitis in osteitis. (b) Coronal sinus CT scan shows hyperostotic ethmoid thickening with concomitant mucosal thickening.

usually be identified by the appearance of a persistently inflamed mucosa. Figure 3 shows the typical endoscopic appearance and CT scan in a recalcitrant CRS patient with concomitant osteitis.

This study showed that there was no significant correlation between GOS before FESS and Lund Mackay endoscopy score after FESS. This situation may occur because at the time of surgery the osteitis in CRS patients had been treated properly. Adequate postoperative therapy includes oral antibiotics, systemic corticosteroids and isotonic nasal irrigation also plays a role in wound healing after surgery. Sacks *et al.* found that the presence of osteitis was associated with the use of corticosteroids.<sup>15</sup> However, the correlation between GOS before FESS and Lund Mackay's endoscopic score after FESS has a positive tendency ( $r = 0.197$ ), with increasing GOS scores before FESS causes Lund Mackay's endoscopic score after FESS will also increase. Snivdongs *et al.* stated patients with Kennedy osteitis score more than 0, had greater endoscopy and CT score than those without osteitis.<sup>16</sup> Previous studies show there were the prevalence of osteitis in the revision ESS group is higher compare to primary ESS group, those studies stated patients with revision ESS had the highest ethmoid bone density, and a greater extent of osteitis found in patients with previous sinus surgery. However, recently the etiology of osteitis is more than a post-surgical phenomenon, there is no clear explanation why patients with primary surgery experience neo-osteogenesis. This review suggest that further studies are required to answer the unclear pathogenesis of osteitis in CRS.<sup>17</sup>

There are intrinsic and extrinsic risk factors for CRS that can affect the prognosis and wound healing after surgery. The clinical study in Kariadi Hospital shows the most common risk factor was allergic rhinitis.<sup>18</sup> Studies in tertiary referral clinics shows from 112 adult CRS patients 56.25% were atopic, 41% with asthma, and among these 53.97 were polysensitized.<sup>19</sup> The other study in tertiary hospital Malaysia shows a significant difference in the endoscopic scoring between both allergy and the nonallergy groups, and there were worsen edema and

polypoidal degeneration of the middle turbinate on both sides in the allergy group.<sup>20</sup> Allergies can be in the form of allergic rhinitis, which is one of the factors causing the failure of surgery.<sup>12</sup> Kirtsreesakul *et al.* stated that mucociliary dysfunction in allergic rhinitis is caused by a hypersensitivity reaction process mediated by Ig E. Allergic inflammatory mediators affect mucociliary transport function, cilia structure and function, and mucus production that cause chronic inflammation.<sup>13</sup>

The second most risk factor that can affect the prognosis and postoperative wound healing in Kariadi hospital study was nasal polyp.<sup>18</sup> This is a benign lesion that arises from paranasal sinuses or nasal mucosal. The recurrence of nasal polyps is quite high and causes recurrent nose surgery.<sup>14</sup> Nasal polyps are one of the factors affecting the post-nose surgery outcome.<sup>18</sup> The other factor that can delayed wound healing after surgery is smoking. Hamizan *et al.* studies shows 66% subjects were diagnosed as chronic rhinosinusitis with nasal polyps (CRSwNP), and 8.93% smoked.<sup>19</sup> Postoperatively, smoking patients show delayed wound healing because of nicotine, carbon monoxide and hydrogen cyanide from cigarette smoke. Nicotine stimulating sympathetic nerve activity that interferes oxygen supply, releasing epinephrine causing peripheral vasoconstriction so that perfusion to the tissue decreases and causing tissue ischemia. Nicotine also reduced fibrinolytic activity and platelet augmentation causing elevation of blood viscosity. Carbon monoxide in cigarette smoke causes tissue hypoxia, by binding to hemoglobin (200 times greater than oxygen). Hydrogen cyanide can damage cellular oxygen metabolism so that oxygenation is disrupted.<sup>9</sup>

In this study the highest risk factor was allergic rhinitis, but for there were no significant correlation between allergic rhinitis, polyps and smoking with Lund Mackay endoscopy score after FESS. FESS is a procedure of remove the pathological mucosal tissue and bone caused by an inflammatory process, to create a conducive environment for normal mucosal regeneration. After FESS the inflammatory process due to chronic

inflammation such as allergic rhinitis, nasal polyps and smoking cessation is decrease, and the improvement of mucosal regeneration shows in endoscopy evaluation.<sup>10</sup>

### CONCLUSION

There is no significant correlation between preoperative osteitis degree (GOS) with endoscopic evaluation (Lund Mackay score) 4 weeks after surgery, but the correlation shows a positive tendency. Allergic rhinitis, polyps, and smoking also show no significant correlation with with the endoscopic evaluation (Lund Mackay score) 4 weeks after surgery.

### REFERENCES

1. RJS, BA W. Chronic rhinosinusitis and polyposis in: Ballenger's Otorhinolaryngology. 17<sup>th</sup> ed. Vol. 2. Connecticut: BC Decker Inc; 2009. 575 p.
2. W B, H N, C P. Ear, Nose and Throat Disease. 3<sup>rd</sup> ed. New York: Thieme; 2009. 242–260 p.
3. Bhandarkar ND, Sautter NB, Kennedy DW, Smith TL. Osteitis in chronic rhinosinusitis: a review of the literature. *Int Forum Allergy Rhinol.* 2013 May;3(5):355–63.
4. Telmesani LM, Al-Shawarby M. Osteitis in chronic rhinosinusitis with nasal polyps: a comparative study between primary and recurrent cases. *European Archives of Oto-Rhino-Laryngology.* 2010 May 6;267(5):721–4.
5. Snidvongs K, McLachlan R, Sacks R, Earls P, Harvey RJ. Correlation of the Kennedy Osteitis Score to clinico-histologic features of chronic rhinosinusitis. *Int Forum Allergy Rhinol.* 2013 May;3(5):369–75.
6. Georgalas C, Videler W, Freling N, Fokkens W. Global Osteitis Scoring Scale and chronic rhinosinusitis: a marker of revision surgery. *Clinical Otolaryngology.* 2010 Dec;35(6):455–61.
7. Fokkens WJ, Lund VJ, Mullol J, Bachert C, Alobid I, Baroody F, et al. EPOS 2012: European position paper on rhinosinusitis and nasal polyps 2012. A summary for otorhinolaryngologists. *Rhinology journal.* 2012 Mar 1;50(1):1–12.
8. Ting F, Hopkins C. Outcome Measures in Chronic Rhinosinusitis. *Curr Otorhinolaryngol Rep.* 2018 Sep 16;6(3):271–5.
9. Guo S, DiPietro LA. Factors Affecting Wound Healing. *J Dent Res.* 2010 Mar 5;89(3):219–29.
10. Yusnita D, Dewi AMK, Hariyati R. Effectiveness of Hyaluronic Acid Nasal Drops in Post Functional Endoscopic Sinus Surgery. *Jurnal Kedokteran Brawijaya.* 2022;32(1):23–7.
11. Snidvongs K, Dalgorf D, Kalish L, Sacks R, Pratt E, Harvey RJ. Modified Lund Mackay Postoperative Endoscopy Score for defining inflammatory burden in chronic rhinosinusitis. *Rhinology journal.* 2014 Mar 1;52(1):53–9.
12. Schubert MS. Allergic fungal sinusitis: pathophysiology, diagnosis and management. *Med Mycol.* 2009 Jan;47(s1):S324–30.
13. Kirtsreesakul V, Somjareonwattana P, Ruttanaphol S. Impact of IgE-Mediated Hypersensitivity on Nasal Mucociliary Clearance. *Arch Otolaryngol Head Neck Surg.* 2010 Aug 16;136(8):801.
14. Galluzzi F, Pignataro L, Maddalone M, Garavello W. Recurrences of surgery for antrochoanal polyps in children: A systematic review. *Int J Pediatr Otorhinolaryngol.* 2018 Mar;106:26–30.
15. Sacks PL, Snidvongs K, Rom D, Earls P, Sacks R, Harvey RJ. The impact of neo-osteogenesis on disease control in chronic rhinosinusitis after primary surgery. *Int Forum Allergy Rhinol.* 2013 Oct;3(10):823–7.
16. Snidvongs K, McLachlan R, Sacks R, Earls P, Harvey RJ. Correlation of the Kennedy Osteitis Score to clinico-histologic features of chronic rhinosinusitis. *Int Forum Allergy Rhinol.* 2013 May;3(5):369–75.
17. Snidvongs K, Sacks R, Harvey RJ. Osteitis in Chronic Rhinosinusitis. *Curr Allergy Asthma Rep.* 2019 Mar 14;19(5):24.
18. Cooper M, Cheng T, Truong T, Kuchibhatla M, Hachem RA, Jang DW. Factors Associated with Revision Surgery after Balloon Sinuplasty. *OtolaryngologyHead and Neck Surgery.* 2019 Apr 20;160(4):734–9.
19. Hamizan AW, Loftus PA, Alvarado R, Ho J, Kalish L, Sacks R, DelGaudio JM, Harvey RJ. Allergic phenotype of chronic rhinosinusitis based on radiologic pattern of disease. *Laryngoscope.* 2018 Sep;128(9):2015–2021.
20. Abdullah B, Vengathajalam S, Md Daud MK, Wan Mohammad Z, Hamizan A, Husain S. The Clinical and Radiological Characterizations of the Allergic Phenotype of Chronic Rhinosinusitis with Nasal Polyps. *J Asthma Allergy.* 2020 Oct 27;13:523–531.